

Detection of blood deprived regions in SIAgraph images of pigmented skin lesions

Francesca Satta^a and Ela Claridge^{b*}

^aEngineering Faculty, University of Florence, Italy.

^bSchool of Computer Science, The University of Birmingham, Birmingham B15 2TT.

Abstract. A clinical study using the SIAscope images for the diagnosis of malignant melanoma has shown that the presence of blood deprivation regions within the lesion is strongly associated with malignancy. This paper presents a computer method for automatic detection of the blood deprived regions. The results of the computer method compared to the clinical assessment show very good agreement, with 91% sensitivity and 96% specificity on the set of 95 lesions.

1 Introduction

Spectrophotometric Intracutaneous Analysis (SIA) is a rapid dermal scanning technique that uses remitted light in the visible and infrared spectra to derive information regarding the skin. It has been developed at Birmingham University, Addenbrooke's Hospital and Astron Clinica and the detailed theory has been presented in previous papers [1] [2]. The clinician is presented with SIAgraphs that are high resolution images showing information on the distribution, location and quantity of various chromophores and other structures throughout a lesion. A clinical study using the SIAscope in the diagnosis of malignant melanoma has identified a number of features in SIAgraphs which are correlated with underlying significant histopathology [3]. They include dermal melanin, blood displacement, erythematous blush and collagen holes. The presence or absence of each feature was visually assessed by two independent observers using standard SIAscope viewing facilities [3]. These features have been found to be highly specific and sensitive for melanoma and they compare very favourably with dermatoscopic features, the current clinical standard, when analysed using ROC curves.

One of the features identified is "blood displacement": a zone where blood is absent within the lesion due to displacement by tumour (this is clinically known as "central pallor"). The results shown in [3] reveal that blood displacement is one of the best indicators in the diagnosis of malignant melanoma, with a good compromise between sensitivity (75%) and specificity (70.3%). Only one other feature called "collagen holes" has a better combination of sensitivity and specificity (78.8% and 74% respectively), but Kappa statistics show that it is less reproducible and reliable. Blood displacement has very good reproducibility (Kappa score around 0.8) and reliability (Kappa score about 0.8). Its negative predictive value is also very high (94.1%).

The above statistics show that blood displacement is an important diagnostic sign in melanoma diagnosis. We present a computer method which automatically determines whether blood displacement is present in the blood SIAgraph of a skin lesion. The results of the computer method are compared to clinical assessment and their sensitivity and specificity as a melanoma indicator are evaluated.

2 Blood SIAgraphs

Melanoma cancer starts when melanocytes reproduce at high abnormal rate in the epidermis. It continues with a descent of abnormal melanocytes into the dermis towards deeper and deeper zones. Depending on the stage and progression of this invasion into the papillary dermis, the pattern and the amount of blood displacement varies widely. These physiological changes are captured by blood SIAgraphs, where blood displacement presents itself in a variety of shapes, textures and sizes. In some images a clearly visible bright blob can be observed, whilst in others only a haphazard "salt and pepper" pattern is displayed. Both kinds are classified by clinicians as positive. Two examples are shown in Figure 1. The bright pixels in blood SIAgraphs indicate points in the skin where level of blood is low. Conversely, dark pixels represent skin zones where the amount of blood is high. Due to this variety of appearance, the automatic extraction of this feature is not straightforward.

3 Objective

The aim of the present study is to develop classification of blood SIAgraphs into two classes: images that contain regions of blood displacement within the lesion, and images that do not. The investigation does not try to perform a detailed segmentation of blood displacement regions.

* (E.Claridge, F.Satta)@cs.bham.ac.uk

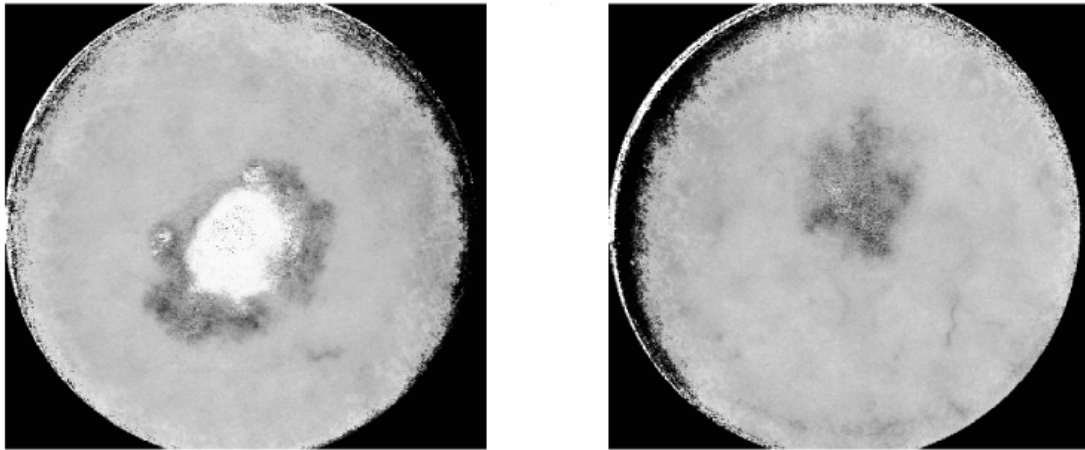


Figure 1. Blood SIAGraphs showing large differences in the appearance of the blood displacement patterns.

4 Materials and methods

4.1 Materials

A total of 95 images were used for this work, of which 45 contained blood displacement according to the classification supplied by two experts. Their assessment was used as the ground truth. The images were subdivided into the training set containing 37 images (12 positive and 25 negative samples) and the test set of 58 images (33 positive and 25 negative samples). All the development work described in sections 4.2 - 4.4 was carried out exclusively on the training set.

4.2 Preprocessing

SIAGraphs sometimes contain artefacts around their borders due to light leakage into the SIAscope's camera field of view. As a result the periphery of the graphs is corrupted by heavy noise. For this reason, prior to the analysis of SIAGraphs a fixed binary circular mask is applied to delete a portion of normal skin corrupted by noise. The resulting image shows the central part of the blood SIAGraph which contains a lesion and also a considerable portion of normal skin. Thus no significant loss of information occurs in the region of interest. Next, the lesion outline is obtained by using an edge localization algorithm based on psychophysical models of edge localization in humans [4]. It is necessary to know which part of the image represents a lesion because blood displacement is diagnostically significant only within the lesion.

4.3 Morphological operations

In order to render the blood displacement region more homogeneous, morphological closing operation [5] is applied to the interior of the lesion, whilst leaving the normal skin region unaltered. The aim of the closing operation is to remove "salt and pepper noise" using a sequence of three consecutive dilations to join bright dots. The structuring element chosen is an 8-nearest neighbours kernel. Next, to shrink the lesion to the original size, a sequence of three erosions is applied using again an 8-nearest neighbours kernel. By merging individual small regions into a larger cluster prevents their disappearance during the subsequent morphological erosion applied to remove hairs as described below.

In a significant proportion of images, body hair is a source of artefacts which mimic blood displacement. As hairs do not contain any blood they appear in blood SIAGraphs as thin bright strips, as shown in Figure 2-c. Thus bright dots can represent the real absence of blood or the presence of hair. Although a software package for removing hairs, called "Dull Razor", is available on the web [6], in this investigation a morphological approach which leads to comparable results has been preferred. Hair thickness is on average no more than two pixels, so a good cleaning of the images can be obtained by using two consecutive erosion operations followed by an equal number of dilations. The structuring element used is, once again, an 8-nearest neighbours kernel. Images in Figure 2 show respectively: (a) an original image with "salt and pepper" blood displacement pattern ; (b) image (a) after morphological processing, where the blood displacement is more clearly visible; (c) an original image with hair (no blood displacement); (d) image (c) after morphological processing where hairs are no longer present within the lesion.

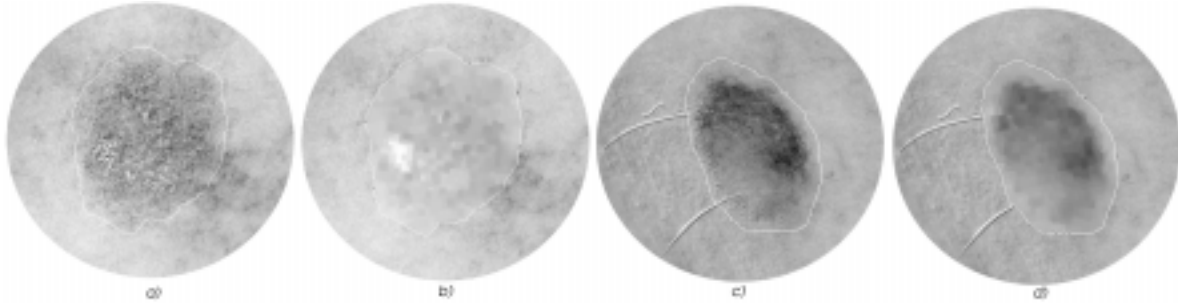


Figure 2. Examples of two blood SIAgraphs: (a) and (c) are originals, (b) and (d) show the results of clustering and hair removal. The white outline shows the lesion boundary.

4.4 Detection of blood displacement

The aim of the preprocessing step was to enhance the information related to the feature in which we are interested in, in order to make it easier to detect automatically. That part of processing dealt only with the lesion interior. In the detection step we consider also the surrounding skin, because its grey level corresponds to a normal level of blood in the vicinity of the lesion. The areas of blood displacement have grey levels higher than those of the skin surrounding the lesion. It should be thus possible to identify the regions of blood displacement by detecting values within the lesion which are higher than those of the skin. Thresholding was the obvious choice and the selection of a threshold value was the next step in the investigation. As the values in SIAgraphs correspond to real physiological quantities, it was expected that a single threshold value would work for all the images.

First, the grey level statistics were computed for the regions containing blood displacement and the regions of the normal skin. For each pre-processed image in the training set the region of blood displacement was outlined by hand, and the skin region was taken to be the portion of the image lying outside the lesion border. The histograms computed for the two regions did not show overlap; moreover, skin histograms had normal distribution. A threshold value for a given image was computed first, on the basis of the skin histogram: if its mean and the standard deviation were μ and σ , the threshold value was chosen at $T = \mu + 2\sigma$. The initial threshold value, to be applied to all the images, was then calculated as the average of all the threshold values T in the training set, with value 206.

A final, optimal, threshold value was then chosen using ROC analysis. An ROC curve was generated by varying the initial threshold value to see which one generates a point in ROC graph closest to (0,1), which represents the best discrimination achievable. This analysis produced the final threshold value of 208, which minimizes the distance between ROC curve and the point (0,1). This optimal value differs from the initial threshold value only by 2 and it reinforces the validity of the initial statistical prediction based on the histogram observations. This optimal threshold value was applied to all 95 images. Images which had pixels above threshold value within the lesion outline were classified as positive.

5 Results

The methods and parameters established on the basis of the training set were applied to the test set with no further modifications. Two sets of results were computed, one showing how well the results of computer classification (blood displacement present or absent) compare with clinical assessment (Sensitivity and Specificity C in Table 1); the other evaluating the automatically detected blood displacement as a melanoma predictor (Sensitivity and Specificity M in Table 1), with histology taken as the ground truth. Table 1 shows the results. Figures 3 and 4 show examples of lesion images and results of detection of blood displacement.

Data	Number	Sensitivity C	Specificity C	Sensitivity M	Specificity M
Training Set	37	0.91	1.00	0.80	0.81
Test Set	58	0.90	0.92	0.80	0.56
Whole Set	95	0.91	0.96	0.80	0.67

Table 1. Results of blood displacement classification (Sensitivity C and Specificity C) and of blood displacement as a melanoma predictor (Sensitivity M and Specificity M). On this particular lesion set sensitivity and specificity of the melanoma prediction by the clinical assessment were 0.80 and 0.62 respectively.

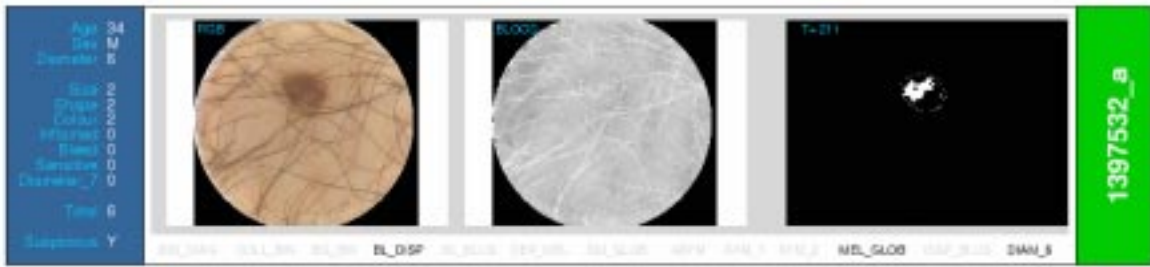


Figure 3. Result of blood displacement detection in an image covered by hair. From left to right: the original colour image, the blood SIAgraph and the blood displacement region together with the lesion overlay

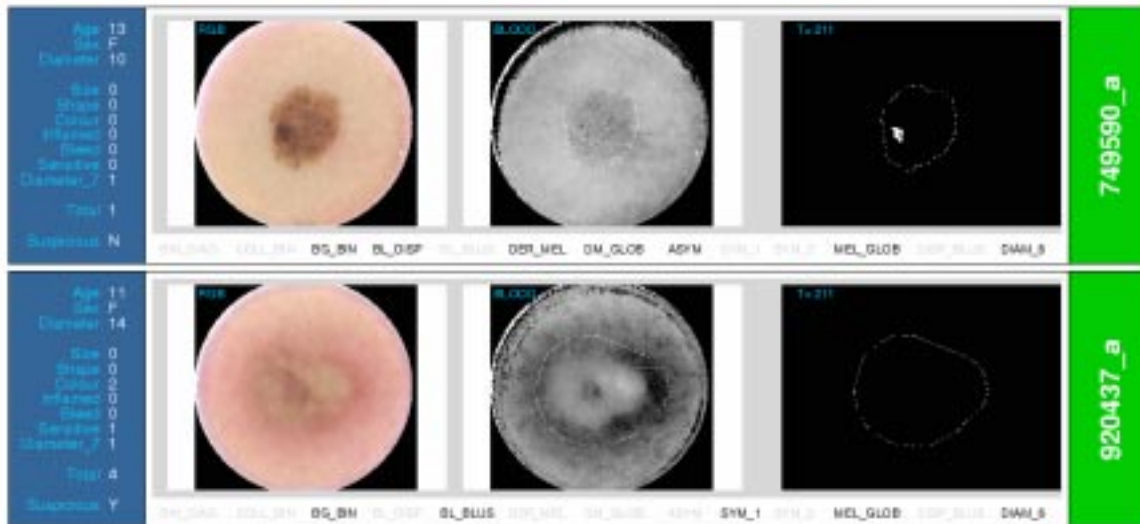


Figure 4. Results of blood displacement detection on a positive and on a negative example.

6 Conclusions

Currently clinicians analyse SIAgraphs visually. The method presented in this paper corresponds very well to experts' assessment. A computer based detection of blood displacement would eliminate the disadvantages of the assessment by human observers, such as the lack of reproducibility. A better method of hair elimination will be sought to prevent the accidental removal of very small blood displacement areas which may happen at present.

SIAgraphs offer a real advantage over other skin imaging methods. Blood displacement, which was found to be a highly significant feature in melanoma diagnosis, is not at all clearly visible in colour images. Further research is underway to automatically detect and quantify others features in SIAgraphs that can be useful in the early detection of melanoma.

7 Acknowledgements

This work is partially supported by EPSRC (grant number GR/M53035).

References

1. S. Cotton, E. Claridge & P. N. Hall. A skin image method based on a colour formation model and its application to the diagnosis of pigmented skin lesion. In *Medical Image Understanding and Analysis*, Hawkes D et al (Eds), 49-52, 1999.
2. S. Cotton, E. Claridge & P. N. Hall. Noninvasive skin imaging. In *Information Processing in Medical Imaging*, Duncan J and Gindi G (Eds): Springer-Verlag, 501-506, 1997.
3. M. Moncrieff, S. Cotton, E. Claridge et al. Spectrophotometric intracutaneous analysis: a new technique for imaging pigmented skin lesion. *British Journal of Dermatology* 146(3), 448-457, 2002.
4. E. Claridge. Boundary localisation algorithm consistent with human visual perception. In *International Conference on Pattern Recognition*, A Venkatesh, S Lovell and BC (Eds), 300-304, 1998.
5. J. Serra. *Image Analysis and Mathematical Morphology*. Academic Press, London, 1982.
6. T. N. V. Lee, R. Gallagher, A. Coldman et al. DullRazor: a software approach to hair removal from images. *Computers in Biology and Medicine* 27, 533-543, 1997.